

American Journal of Sports Medicine

<http://ajs.sagepub.com>

Open Capsular Repair Without Bone Block for Recurrent Anterior Shoulder Instability in Patients With and Without Bony Defects of the Glenoid and/or Humeral Head

Michael J. Pagnani

Am. J. Sports Med. 2008; 36; 1805 originally published online Apr 30, 2008;
DOI: 10.1177/0363546508316284

The online version of this article can be found at:
<http://ajs.sagepub.com/cgi/content/abstract/36/9/1805>

Published by:

 SAGE Publications

<http://www.sagepublications.com>

On behalf of:



[American Orthopaedic Society for Sports Medicine](http://www.aossm.org)

Additional services and information for *American Journal of Sports Medicine* can be found at:

Email Alerts: <http://ajs.sagepub.com/cgi/alerts>

Subscriptions: <http://ajs.sagepub.com/subscriptions>

Reprints: <http://www.sagepub.com/journalsReprints.nav>

Permissions: <http://www.sagepub.com/journalsPermissions.nav>

Citations (this article cites 41 articles hosted on the
SAGE Journals Online and HighWire Press platforms):
<http://ajs.sagepub.com/cgi/content/abstract/36/9/1805#BIBL>

Open Capsular Repair Without Bone Block for Recurrent Anterior Shoulder Instability in Patients With and Without Bony Defects of the Glenoid and/or Humeral Head

Michael J. Pagnani, MD

From the Nashville Knee & Shoulder Center, Nashville, Tennessee

Background: Bony defects of the humeral head and glenoid have been associated with high failure rates after arthroscopic stabilization for anterior instability. Biomechanical studies have indicated that such lesions reduce stability and may predispose to failure and motion loss after capsular repair.

Purpose: The present investigation was designed to evaluate the effect of bony deficiency of the glenoid and/or humeral head on recurrence rates with a conventional open technique of anterior stabilization without a bone block.

Study Design: Case series; Level of evidence, 4.

Materials and Methods: One hundred nineteen consecutive patients with recurrent anterior shoulder instability were treated by a single surgeon with an open anterior stabilization procedure. Patients were studied prospectively for recurrent instability after the presence and size of bony defects of the humeral head and/or glenoid were recorded during an arthroscopic examination before the open procedure. One hundred three patients (mean age, 20.7 years), including 98 men and 5 women, were available for 2-year minimum follow-up. Eighty-three of the patients participated in contact athletics.

Results: Eighty-four percent of the patients had demonstrable Hill-Sachs lesions at the time of arthroscopy (27% “engaging” and 57% “nonengaging”). Fourteen percent had deficiency of the anterior glenoid, 9% had large (Rowe classification) defects of the humeral head, and 4% had severe (>20%) defects of the glenoid. The overall recurrence rate was 2%. Both recurrences were noted in patients with Hill-Sachs lesions, but the recurrence rate in patients with Hill-Sachs lesions was not significantly higher ($P = .71$). There was 1 recurrence among the 9 patients with large defects of the humeral head ($P = .17$). Patients with engaging Hill-Sachs lesions did not have a statistically significant increase in recurrence (4%) ($P = .47$). There were no recurrences in patients with glenoid deficiency. Patients with large defects of the glenoid lost a mean of 7° of external rotation ($P = .001$) when compared with the remaining population (12° vs 5°). Patients with large defects of the humeral head lost a mean of 4° more external rotation ($P = .003$) when compared with the remaining population (9° vs 5°). Two patients in the series lost $\geq 20^\circ$ of external rotation. When contact athletes were isolated as a population, there were no statistically significant increases in recurrence due to the presence of bony lesions of the glenoid or humeral head.

Conclusion: Bony defects of the humeral head or glenoid did not appear to result in a statistically significant increase in the risk of recurrence with conventional open techniques of stabilization. Large defects on either side of the joint were uncommon in the study population. Bone-block or grafting procedures do not appear to be necessary to restore stability in the majority of patients with bone loss. Although the loss of external rotation in patients with large defects is a relative cause for concern, the author recommends open capsular repair as the primary method of treatment given the high complication rate historically associated with bone-block techniques.

Keywords: shoulder; instability; open stabilization; bony defect; glenoid; Hill-Sachs

Several recent investigations have analyzed the effects of bony defects of the humeral head and glenoid on anterior

shoulder stability.* Clinically, Burkhart and de Beer⁶ reported high failure rates in patients with bony deficiency after arthroscopic Bankart repair. Biomechanical studies have indicated that a capsular repair alone may be insufficient to maintain stability in the presence of a glenoid defect^{12,20,27} and that stability is diminished in the presence of a large defect of the humeral head.³⁷ In addition, Itoi et al²⁰ found that external rotation of the

Address correspondence to Michael J. Pagnani, MD, Nashville Knee & Shoulder Center, 2011 Church Street, Suite 505, Nashville, TN 37203 (e-mail: mjp@nashvilleknee.com).

No potential conflict of interest declared.

The American Journal of Sports Medicine, Vol. 36, No. 9
DOI: 10.1177/0363546508316284

© 2008 American Orthopaedic Society for Sports Medicine

*References 3, 4, 6, 8, 11, 12, 20, 23-25, 27, 36, 37, 41

humerus became restricted after capsular repair in the presence of a sizable glenoid defect in a cadaveric model.

At least in part due to the concerns noted above, a number of bone augmentation procedures have recently been recommended in selected patients with anterior instability and bone loss involving the humeral head or glenoid. Auffarth et al³ and Warner et al⁴¹ reported on iliac crest bone grafting of the glenoid in selected cases of glenoid deficiency. Burkhart and de Beer⁶ advised performance of the Latarjet procedure in patients with glenoid deficiency. Gerber¹¹ and Miniaci and Gish²⁵ have described osteochondral allografts to the humeral head in patients with large Hill-Sachs lesions.¹⁸

A review of the existing literature suggests that open Bankart repair has yielded results that have been deemed acceptable in patients with bony defects of the glenoid and/or humeral head.^{4,14,15,33,34} Despite a recurrence rate reported to be as high as 67% after arthroscopic stabilization in patients with bone loss,^{5,6} recurrence rates after open stabilization have ranged from 2.5% to 12% in the same population.^{4,14,15,33,34} The present investigation was designed to determine the recurrence rates with a conventional technique of open anterior stabilization^{28,29} without bony augmentation in patients with defects of the glenoid and/or humeral head. In addition, the influence of bone loss on postoperative external rotation was assessed after open capsular repair.

MATERIALS AND METHODS

One hundred nineteen consecutive patients with recurrent anterior shoulder instability were treated with open anterior stabilization procedure by a single surgeon over a 6-year period from 2000 through 2005. Ninety-five patients were treated for recurrent anterior dislocations, and 24 had recurrent anterior subluxations of the shoulder. No patient in this series underwent surgery after a first-time dislocation. All patients who underwent surgical treatment failed a trial of nonoperative treatment that included a standardized physical therapy rehabilitation protocol and abduction bracing for selected positions in contact athletics. During the study period, a number of patients who were treated for anterior instability fared well with nonoperative treatment and did not go on to an operation.

The indication for surgical stabilization was, generally, recurrent instability that interfered with athletic activity or activities of daily life despite nonoperative treatment. During this period, all patients whose focus of participation was in contact athletics were treated with an open technique. All patients who focused on throwing and overhead sports were treated with an arthroscopic technique.

Patients who did not participate in either of the above athletic pursuits were generally advised that historical recurrence rates were higher after arthroscopic procedures than after open procedures and were individualized to open or arthroscopic stabilization. In general, more active and less sedentary patients in this group were treated with an open technique, while less active and more sedentary patients were treated by arthroscopic methods. During the study period, 73 patients were treated with arthroscopic stabilization. Patients who underwent arthroscopic stabilization were

not analyzed for this study. Patients who had undergone a previous surgical intervention for instability were also excluded from the present series.

One hundred three patients were available at 2-year minimum follow-up (range, 24-74 months). Sixteen patients were lost to follow-up. The mean age of those patients available for evaluation was 20.7 years (range, 15-52). Ninety-eight male and 5 female patients were included in this group. The dominant arm was involved in 74 of the patients. Eighty-three of the 103 patients participated in contact athletics (as defined by the American Academy of Pediatrics²) before their procedure.

Anteroposterior, axillary, supraspinatus outlet, Stryker notch,¹⁶ and West Point axillary views¹⁰ were routinely obtained during the clinical evaluation of patients with a diagnosis of anterior instability. These radiographs were analyzed for the presence and size of bony defects of the glenoid or humeral head.

All patients underwent arthroscopic examination of the shoulder immediately before the open procedure, and the presence and size of bony lesions were recorded for both glenoid and humeral surfaces.

Glenoid lesions were measured as a percentage of the maximum anteroposterior diameter of the glenoid as described by Burkhart et al⁷ and Lo et al²³ using the "bare area" of the glenoid surface as a reference point. With the arthroscope in an anterosuperior portal, a small right-angle arthroscopic probe with a 4-mm tip and 1-mm longitudinal markings was placed in a posterior portal and used to measure the distance (B) from the posterior glenoid margin to the bare area. A similar measurement (A) was made from the bare area to the anterior glenoid margin. The defect was then expressed by the formula as described by Lo et al²³:

$$\text{percentage loss of glenoid width} = (B-A)/B \times 100\%$$

Hill-Sachs lesions of the humeral head¹⁶ were classified according to the system devised by Rowe et al³⁴ (mild, 2 cm long and 0.3 cm deep; moderate, 4 cm long and 0.5 cm deep; severe, 4 cm long and 1 cm deep). Patients with moderate or severe Rowe lesions were considered to have "large" defects. Although this system was not designed for arthroscopic measurement, it was easily extrapolated for arthroscopic usage. I am not aware of any comparable arthroscopic classification system for Hill-Sachs lesions. With the arthroscope in the posterior portal, the same probe was introduced through the anterior or anterosuperior portal and was used to determine the depth and length of the lesion. Hill-Sachs lesions were also divided into "engaging" and "nonengaging" types based on the descriptions of Burkhart and de Beer.⁶

In an "engaging" lesion, the humeral head defect engages the anterior glenoid in a "position of function (ie, 90° of abduction combined with external rotation anywhere from 0 to 135°)." The lesion presents the long axis of its defect parallel to the anterior glenoid with the shoulder in a functional position of abduction and external rotation, so that the Hill-Sachs lesion engages the corner of the glenoid.

With a "nonengaging" lesion, the long axis of the defect encounters the glenoid on a diagonal, nonparallel angle. However, a nonengaging lesion may engage the anterior

glenoid in low ranges of abduction ($<70^\circ$) or in the “non-functional” position of shoulder extension.

If clinically indicated, a computed tomography (CT) scan was obtained to evaluate larger bony defects (5 patients) in the earlier part of the study. Later in the study period, it was concluded that a CT scan was unnecessary to demonstrate the size of the lesions, and CT scans were not obtained. During the study period, it became evident that an arthroscopic method of measuring the bony defects was a more accurate and objective method than radiographic measurement. The arthroscopic measurements were therefore used for all further analysis. Specifically, the CT tended to overestimate the size of larger glenoid lesions, and the CT measurement of smaller lesions was not superior to arthroscopic measurement. These phenomena have been previously noted by others.^{19,38} In the current study, the findings on CT scan did not alter the management at operation or during rehabilitation.

After the arthroscopic documentation of the presence and size of bony defects of the glenoid and/or humeral head, the patient underwent an open stabilization procedure.

Open Surgical Technique^{28,29}

An anterior deltopectoral approach was used. A vertical tenotomy of the subscapularis tendon was performed with electrocautery approximately 1 cm medial to insertion on the lesser tuberosity. The interval between the anterior aspect of the capsule and the subscapularis tendon was then carefully developed with a combination of blunt and sharp dissection.

Any opening of the capsule in the area between the subscapularis and the supraspinatus was considered to be a “rotator interval lesion.” If there was a lesion in the rotator interval, it was generally closed at this point with No. 1 nonabsorbable braided polyester sutures. A transverse capsulotomy was then performed (Figure 1), and a ring (Fukuda) retractor was placed intra-articularly.

If a Bankart lesion was noted, the capsulolabral separation at the anteroinferior glenoid neck was extended medially with use of an elevator or knife to allow placement of a retractor along the glenoid neck. Any glenoid rim fragment was sharply dissected from the anterior capsule and labrum and discarded. No other modification of the technique was made in the presence of a bony defect of the glenoid or humeral head. The glenoid neck was then roughened to provide a bleeding surface. Two or 3 metallic suture anchors were placed in the anteroinferior glenoid neck near, but not on, the articular margin of the glenoid. The arm was placed in 45° of abduction and 45° of external rotation during the capsular repair. The inferior capsular flap was then mobilized slightly medially and superiorly, and this flap was used to repair the Bankart lesion. The inferior flap was reattached to the anterior aspect of the glenoid to repair the Bankart lesion using the suture anchors (Figure 2).

After repair of the Bankart lesion (or in the absence of a Bankart lesion), an anterior capsulorrhaphy was performed to eliminate excess capsular laxity. The arm was maintained in 45° of abduction and 45° of external rotation, and the

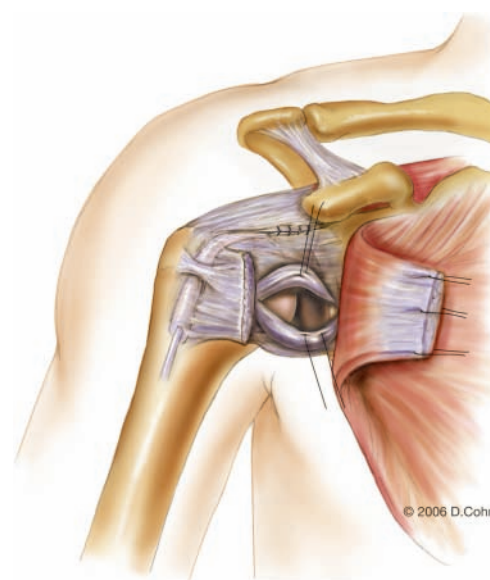


Figure 1. Transverse capsulotomy after closure of the rotator interval. (Reproduced with permission from the illustrator, Delilah Cohn, MFA, CMI.)

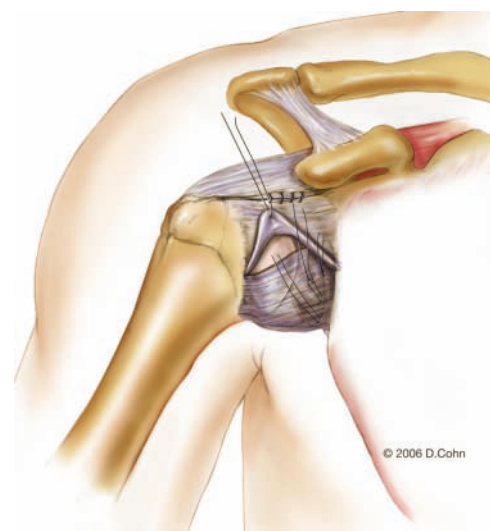


Figure 2. The inferior capsular flap is used to repair the Bankart lesion after being mobilized slightly medially and superiorly. (Reproduced with permission from the illustrator, Delilah Cohn, MFA, CMI.)

superior and inferior capsular flaps were reapproximated with forceps. The shoulder was held in a reduced position. If the capsular flaps could be overlapped, the capsule was shifted to eliminate excess capsular volume. If there were ≤ 5 mm of overlap at any point along the horizontal capsular incision, the capsule was imbricated by shifting the superior flap over the inferior flap and passing the sutures a second time through the superior flap (Figure 3). With >5 mm of capsular overlap, the capsulotomy was extended in a vertical direction near its lateral insertion on the humeral neck to approximately the 6 o'clock position on

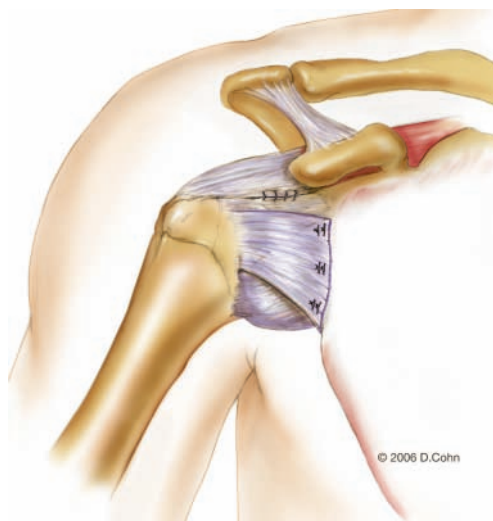


Figure 3. The superior flap is shifted over the inferior flap, and the sutures are passed a second time through the superior flap. (Reproduced with permission from the illustrator, Delilah Cohn, MFA, CMI.)

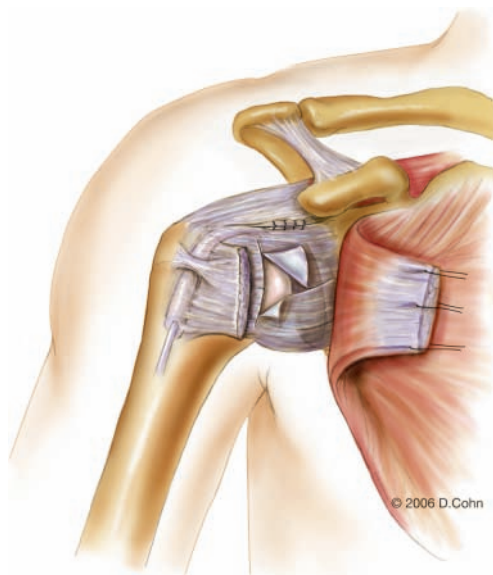


Figure 4. In cases with more significant capsular laxity, the capsulotomy is extended vertically near the humeral insertion, and the flaps are shifted to a greater degree. (Reproduced with permission from the illustrator, Delilah Cohn, MFA, CMI.)

the neck, and a T-plasty capsular shift was performed (Figure 4). The inferior capsular flap was shifted superolaterally, and the superior flap was moved over the inferior flap in an inferolateral direction. The transverse portion of the capsulotomy was then closed.

After the capsule was addressed satisfactorily, the subscapularis was reapproximated, but not shortened, with nonabsorbable suture. The deltopectoral interval was loosely closed with absorbable suture. Routine wound closure was then performed.

Postoperative Rehabilitation Protocol^{28,29}

All patients had their shoulders immobilized in a sling in a position of internal rotation for 4 weeks after the operation. During the initial 4 weeks, the sling was removed for pendulum exercises, elbow range of motion, and shoulder shrugs.

Passive- and active-assisted shoulder range of motion was instituted 4 weeks postoperatively with external rotation limited to 45°. When 140° of active forward flexion was obtained, rotator cuff strengthening was initiated with the arm at low abduction angles.

From weeks 8 to 12, external rotation continued to be restricted to 45°. At this time, deltoid isometrics with the arm at low abduction levels and body blade exercises were started. If no impingement or rotator cuff symptoms were noted, the patient slowly increased abduction during rotator cuff and deltoid strengthening. Scapular rotator strengthening including press-ups (seated dips), horizontal abduction exercises, and open-can exercises were progressed.

Beginning at week 12, an effort was made to restore terminal external rotation. Proprioceptive neuromuscular feedback patterns, plyometric exercises, and sport-specific motion using a pulley, wand, or manual resistance were added to the program.

Conventional weight training was allowed after week 18. Patients were oriented for a return to their sport and were progressed from field drills to contact drills. Abduction harnesses were fitted when appropriate based on sport and position. Return to full contact was allowed when abduction and rotation strength were symmetrical on manual muscle testing—usually between 4.5 and 6 months after operation.

Follow-up and Analysis

After the procedure and documentation of the bony defects, patients were followed prospectively for recurrent instability including postoperative subluxation or dislocation. Patients were assessed using the American Shoulder and Elbow Surgeons shoulder scoring system,³² and complaints of instability or evidence of apprehension were noted. External rotation of the humerus in 90° of abduction was analyzed postoperatively and compared with that of the contralateral shoulder. Apprehension and external rotation were assessed with manual stabilization of the medial border of the scapula.

Statistical analysis was performed using the Fisher exact test for categorical data and Student *t* test for continuous data with the *P* value set at .05.

RESULTS

Incidence of Bony Lesions of the Humeral Head and Glenoid

Eighty-seven patients (84%) had Hill-Sachs lesions. Nine patients (9%) had moderate or severe defects of the humeral head according to the Rowe³⁴ classification. Because Rowe found that patients in both of these categories were at increased risk for recurrence, patients with moderate or severe Rowe defects were considered together

as "large" defects of the humeral head for the purpose of statistical analysis. Twenty-eight patients (27%) had engaging Hill-Sachs lesions according to the description of Burkhart and de Beer,⁶ and 59 (57%) had nonengaging lesions.

Hill-Sachs lesions were found in 68 of the 83 contact athletes (82%). In these contact athletes, 19 lesions were classified as engaging and 49 as nonengaging. Six of the contact athletes had large defects of the humeral head.

Fourteen patients (14%) had defects of the glenoid rim. Four patients (4%) had defects that involved >20% of glenoid diameter and were classified as severe. The largest glenoid defect measured 30% of the maximum anteroposterior diameter of the glenoid. The mean age of the patients with glenoid deficiency of 30.5 years (range, 15-52) was significantly greater than the age of the rest of the population ($P < .001$). In the patients with severe defects, the mean age was 31.3 years (range, 18-47) ($P = .001$). Twelve of the 14 patients with glenoid rim defects also had Hill-Sachs lesions; in 3 of these patients, the Hill-Sachs lesions were classified as large.

Six of the contact athletes (7%) were noted to have bony defects of the glenoid. One patient had severe defects on both sides of the joint.

Recurrence

The overall recurrence rate was 2% (2/103) (Table 1). One patient experienced a dislocation postoperatively. Another patient experienced recurrent postoperative subluxation. The recurrence rate in patients with Hill-Sachs lesions was not statistically higher ($P = .71$) at 2% (2/87). Patients with engaging Hill-Sachs lesions had a 4% recurrence (1/28), but this was not statistically significant ($P = .47$). One of the 9 patients (11%) with large defects of the humeral head according to the Rowe classification had a recurrence ($P = .17$). There were no recurrences in the 14 patients with glenoid rim deficiency.

Two of the 83 contact athletes had recurrent instability (2%). The recurrence in contact athletes with Hill-Sachs lesions was not significantly greater than in those who did not have Hill-Sachs lesions ($P = .68$). Recurrence in contact athletes with engaging lesions (1 recurrence in 19 patients) was 5%—again, not significantly greater than the remaining patients ($P = .33$). One of the 6 contact athletes with a large Hill-Sachs lesion had recurrent instability ($P = .11$).

None of the 6 contact athletes with glenoid defects had recurrent instability.

American Shoulder and Elbow Surgeons Scores³²

The mean postoperative shoulder score according to the scale of the American Shoulder and Elbow Surgeons was 97.4 (range, 73-100) for the entire population. The mean score was 97.3 points (range, 78-100) in all patients with defects of the glenoid rim and 93.25 (range, 78-100) in patients with large glenoid defects. Patients with engaging Hill-Sachs lesions had an average score of 96.6 (range, 73-100). The mean score was 95.2 (range, 78-100) in patients with large Hill-Sachs lesions. There were no statistically significant differences in shoulder scores between these groups.

TABLE 1
Postoperative Recurrence

Group	Recurrence Rate	N	P Value
Overall	2%	2/103	
Patients with Hill-Sachs lesions	2%	2/87	
Large defects of the humeral head	11%	1/9	.17
Engaging Hill-Sachs lesions	4%	1/28	.47
Nonengaging Hill-Sachs lesions	2%	1/59	
Glenoid deficiency	0	0/14	
Contact athletes	2%	2/83	
Athletes with Hill-Sachs lesions	3%	2/68	.68
Engaging lesions	5%	1/19	.33
Nonengaging lesions	2%	1/49	
Glenoid deficiency	0	0/6	

Range of Motion

External rotation of the humerus in 90° of abduction was decreased a mean of 5° in the overall group of 103 patients when compared with that of the contralateral shoulder.

Patients with Hill-Sachs lesions ($n = 87$) lost a mean of 5° (range, 0°-25°), compared with 4° (range, 0°-15°) in patients ($n = 16$) who did not demonstrate a Hill-Sachs lesion ($P = .627$). Patients with moderate or severe Hill-Sachs lesions ($n = 9$) according to the Rowe classification lost a mean of 9° (range, 5°-25°) of external rotation, compared with 5° (range, 0°-20°) in patients ($n = 94$) who did not have such a lesion ($P = .003$). Patients with engaging Hill-Sachs lesions ($n = 28$) lost a mean of 7° (range, 0°-25°), compared with a mean loss of 4° (range, 0°-20°) in all other patients ($n = 75$) ($P = .157$) and a mean loss of 4° (range, 0°-20°) in patients with nonengaging lesions ($n = 59$) ($P = .172$).

Patients with defects of the glenoid rim ($n = 14$) lost a mean of 7° (range, 0°-25°) of external rotation, compared with a 4° loss (range, 0°-15°) of external rotation in patients ($n = 89$) who did not have a glenoid defect ($P = .034$). Patients with large defects (>20%) of the glenoid ($n = 4$) lost a mean of 12° (range, 2°-25°) of external rotation, compared with 5° (range, 0°-15°) in those who did not have a large defect ($P = .001$).

Two patients lost $\geq 20^\circ$ of external rotation. Both of these patients had large glenoid rim defects. One of the 2 was the only patient in this series who had large defects of both the humeral head and glenoid.

Return to Contact Sports

Seventy-six of the 83 contact athletes (92%) returned to full participation in contact sports. Only one of the 7 who did not return was unable to compete because of the postoperative shoulder; this was the same patient who suffered a postoperative dislocation. The patient with postoperative subluxation was able to continue participation despite occasional, mild instability episodes.

The remaining 6 patients did not return to contact sports for reasons unrelated to their shoulders.

DISCUSSION

The principal findings of this study demonstrate that (1) large defects of the humeral head and/or glenoid are uncommon findings over a 6-year period in a large, tertiary referral shoulder practice with a large percentage of contact athletes and (2) satisfactory results can be obtained in most patients with bony defects using a conventional open capsular repair without bony augmentation.

A review of the few published reports of open capsular repair in the face of defects of the glenoid shows that the results have been deemed acceptable. Rowe et al,³³ in their historic 1978 end-result study of open Bankart repairs, found that the postoperative recurrence actually decreased, from 3.5% to 2%, in patients with defects of the glenoid rim. Bigliani et al⁴ reported a 12% recurrence rate after open capsular shift in patients with glenoid bone loss. Interestingly, in 2 separate analyses of failed open instability repairs performed at 2 different internationally renowned centers in the field of instability surgery,^{21,44} excess capsular laxity (and not bony deficiency) was thought to be the primary cause of failure. Although at least some of the patients in the series of Bigliani et al⁴ had defects that may have been larger than those encountered in this series, these reports could lead one to question the need to perform bone augmentation in patients with glenoid insufficiency except in rare cases.

The results in this series are similar to those reported by Rowe et al,³³ who noted a slight decrease in recurrence in patients with glenoid deficiency. In this series, no recurrences were found in patients with bony defects of the glenoid rim. It seems evident that loss of the bony concavity of the glenoid would reduce the stability of the glenohumeral joint. However, my results indicate that, in most circumstances, this loss of stability can be controlled by restoring the capsulolabral complex to the glenoid. It should be noted that none of my 103 patients had a defect that exceeded 30% of the maximum anteroposterior diameter of the glenoid. In addition, the patients with glenoid defects in this series were significantly older than the remaining population. It is possible that aging increases the risk of glenoid insufficiency in patients with instability, although this relationship has not been discussed previously. Older patients are well known to be at lower risk for recurrent shoulder instability than younger patients. In a younger population of patients with glenoid rim lesions or in a population of patients with larger defects, a higher recurrence rate may well be encountered. These factors may explain why the rate in this study is lower than the 2.5% rate reported by Rowe et al³³ and the 12% failure rate noted by Bigliani et al.⁴

Rowe et al³³ found a slight increase in recurrence after open Bankart repair in patients with moderate or severe Hill-Sachs lesions (5% vs 3.5%). Gill et al,^{14,15} in a more recent series of open Bankart repairs, found that their recurrence rate doubled from 3% to 6% in the presence of a large Hill-Sachs lesion.

Both of the recurrences in this series occurred in patients with Hill-Sachs lesions. Although the rate of recurrence in patients with Hill-Sachs lesions was not statistically greater than those who did not have a humeral head defect, the small number of patients with recurrence may obscure a possible relationship. The findings in this study do not necessarily contradict the assertion that the presence of a Hill-Sachs lesion increases the risk of failure after open capsular repair. The results indicate, however, that the risk of recurrence remains low in the presence of such a defect.

Burkhart and de Beer⁶ reported high failure rates after arthroscopic Bankart repair in patients with bony deficiency. In their series, contact athletes who had an engaging Hill-Sachs lesion or "inverted-pear" glenoid had a recurrence rate of 89%. Their subdivision of Hill-Sachs lesions into engaging and nonengaging types is commonly used in contemporary lectures on shoulder instability. Despite the fact that only 3 patients in their series had engaging lesions, it has become accepted in many circles that such lesions increase the risk of failure with arthroscopic capsular repair,¹ and this impression is sometimes generalized to open capsular repair as well. However, more recent studies by Sugaya et al³⁹ and Mologne et al²⁶ dispute the contention that high failure rates can be expected after arthroscopic stabilization in the presence of bony deficiencies of the glenoid.

The division of patients into engaging and nonengaging categories is somewhat subjective. In their original description, Burkhart and de Beer⁶ reported that some nonengaging lesions do, in fact, engage the glenoid in the nonfunctional positions of extension or low levels of abduction. Because Hill-Sachs lesions are impression fractures that occur as the humerus exits and re-enters the glenoid cavity, they must engage the glenoid rim at some point. Despite adherence to the guidelines provided by Burkhart and de Beer in differentiating the lesions, the subjectivity of interpretation may explain the higher relative incidence of engaging lesions in this series compared with theirs. The categorization of Hill-Sachs lesions into engaging and nonengaging types is problematic in my estimation. A study of interobserver reliability with regard to this classification would be of interest. One of the 9 patients with a large defect of the humeral head had recurrent instability in the present series; I feel that the size of the lesion has more clinical relevance than its classification as engaging or nonengaging.

Itoi et al²⁰ found that the creation of defects of the anterior glenoid in a cadaveric model reduced anterior stability with the humerus in an abducted and internally rotated position when the defect was larger than approximately one fifth of the glenoid diameter. However, in the position of abduction and external rotation that is most commonly associated with anterior instability, they found no effect on stability—even when the defect approached one half of the glenoid diameter. Gerber and Nyffeller¹² have also reported that the force required for dislocation was reduced when a soft-tissue Bankart repair was performed experimentally in the setting of glenoid deficiency. In a cadaveric biomechanical model, Sekiya et al³⁷ reported that lesions involving >25% of the humeral head engaged the glenoid with

less anterior translation and a lower anterior translating force. Smaller lesions had no effect. It is unlikely that any of the Hill-Sachs lesions in this series exceeded the critical 25% level suggested by Sekiya et al. These clinical and biomechanical studies have led some authors^{8,24,27,41} to postulate that conventional capsular repair may be insufficient in selected patients with bony deficiency of the glenoid and/or humeral head.

Historically, the Bristow,¹⁷ Laterjet,²¹ and Trillat⁴⁰ coracoid transfer procedures were designed to address instability by creating an anterior bony buttress. However, procedures of this type raise several concerns. They do not address capsular laxity or capsulolabral separation, there is a high risk of complications from hardware loosening or nonunion,^{1,36,45} revision surgery is difficult,⁴³ and there is a high incidence of postoperative arthrosis.¹ Despite these reported concerns, Burkhart and de Beer recommended an open Laterjet procedure in cases of glenoid deficiency.⁶ Bigliani et al⁴ have also recommended coracoid transfer when the glenoid defect exceeds 25% of the glenoid diameter. Warner et al⁴¹ described 11 cases in which an autogenous iliac crest bone graft was used to augment glenoid deficiency, and Montgomery et al²⁷ reported that such a graft restored "balance-stability" to shoulders with a deficient glenoid rim. Auffarth et al³ recently reported excellent clinical outcomes after a modified open technique of iliac crest bone grafting in 47 shoulders despite finding radiographic evidence of arthrosis in 40% of their cases. Recent reviews of shoulder instability have concurred that bone augmentation should be considered in selected cases of glenoid deficiency.^{8,22}

Historically, infraspinatus transfer⁹ and rotational humeral osteotomy⁴² have been recommended in patients with large defects of the humeral head. More recently, osteochondral allograft transplantation^{11,25} has been performed in selected patients with such lesions. Interestingly, Burkhart and de Beer recommended open capsular shift in patients with engaging Hill-Sachs lesions.⁶ They did not recommend bony augmentation for humeral head defects. Again, the relatively low recurrence rates reported after open capsular repair in the face of large Hill-Sachs lesions led us to question the necessity of bone augmentation except in rare situations.

In the current investigation of open capsular repair, patients with engaging lesions of the humeral head or defects of the glenoid did not have a statistically significant increase in recurrence in contrast to the report of Burkhart and de Beer,⁶ which showed a dramatic increase in failure in patients with such lesions after arthroscopic repair. This discrepancy would indicate an inherent difference between arthroscopic and open capsular repairs, despite recent reports of satisfactory results after arthroscopic repair in the presence of bony defects of the glenoid.^{26,39} Possible advantages of open repair were discussed in a previous study.²⁹ I believe that the open technique offers certain advantages that are difficult to duplicate with current arthroscopic technology. First, the ability to restore tension to the capsule in a precise manner is facilitated by freeing the capsule from the adherent subscapularis tendon. Second, the shoulder can be maintained in an optimal position during the capsular repair

with less concern about visualization. Third, the capsular structures can be overlapped with ease with use of the open technique. (The ability to reinforce and thicken a damaged capsule may be especially important in an athletic population.) Fourth, the rotator interval, which is difficult to visualize properly through the arthroscope, can be directly observed and properly repaired with the open technique. Recent biomechanical studies^{30,31} have confirmed that open and arthroscopic rotator interval closures differ in their effects on glenohumeral stability.

Loss of motion after instability surgery has been associated with the development of glenohumeral arthritis. In this series, a statistically significant decrease was found in external rotation of the abducted humerus in patients with glenoid defects and in patients with large defects of the humeral head. Loss of motion in patients with glenoid defects was not surprising given the findings in biomechanical studies by Itoi et al²⁰ and Gerber et al¹³ that predicted loss of external rotation with capsular repair in such a population. The finding of decreased external rotation in patients with large Hill-Sachs lesions remains unexplained. No intentional increased capsular tension was created at the time of operation when such lesions were encountered.

Overall, the absolute loss of motion in the series was relatively small. The mean loss of external rotation of 12° in patients with large defects of the glenoid is comparable with the 14° loss described by Warner et al⁴¹ in patients who underwent iliac crest bone grafting for similar lesions. Larger losses of external rotation have been reported after coracoid transfer.¹

Based on the low rates of recurrence in this series, motion loss that is equal to or better than that reported with bone-block procedures, and the seemingly self-evident premise that the complication rate of capsular repair alone should be lower than that of capsular repair combined with bone augmentation, it appears that bone-block or grafting procedures are not necessary in the majority of patients with bony defects of the glenoid or humeral head.

REFERENCES

- Allain J, Goutallier D, Glorion C. Long-term results of the Laterjet procedure for the treatment of anterior instability of the shoulder. *J Bone Joint Surg Am.* 1998;80:841-852.
- American Academy of Pediatrics Committee on Sports Medicine and Fitness. Medical conditions affecting sports participation. *Pediatrics.* 2001;107:1205-1209.
- Auffarth A, Schauer J, Matis N, Kofler B, Hitzl W, Resch H. The J-bone graft for anatomical glenoid reconstruction in recurrent posttraumatic anterior shoulder dislocation. *Am J Sports Med.* 2007 Nov 15 [Epub ahead of print].
- Bigliani LU, Newton PM, Steinmann SP, Connor PM, McIlveen SJ. Glenoid rim lesions associated with recurrent anterior dislocation of the shoulder. *Am J Sports Med.* 1998;26:41-45.
- Boileau P, Villalba M, Hery J-Y, Balg F, Ahrens P, Neyton L. Risk factors for recurrence of anterior instability after arthroscopic Bankart repair. *J Bone Joint Surg Am.* 2006;88:1755-1763.
- Burkhart SS, de Beer JF. Traumatic glenohumeral bone defects and their relationship to failure of arthroscopic Bankart repairs: significance of the inverted pear glenoid and the humeral head engaging Hill-Sachs lesion. *Arthroscopy.* 2000;16:677-694.

7. Burkhart SS, de Beer JF, Tehrany AM, Parten PM. Quantifying bone loss arthroscopically in shoulder instability. *Arthroscopy*. 2002;18:488-491.
8. Chen AL, Hunt SA, Hawkins RJ, Zuckerman JD. Management of bone loss associated with recurrent anterior glenohumeral instability. *Am J Sports Med*. 2005;33:912-925.
9. Connolly JF. Humeral head defects associated with shoulder dislocation: their diagnostic and surgical significance. *Instr Course Lect*. 1972;21:42-54.
10. Danzig LA, Greenway G, Resnick D. The Hill-Sachs lesion: an experimental study. *Am J Sports Med*. 1980;8:328-332.
11. Gerber C. Chronic locked anterior and posterior dislocations. In: Warner JJP, Iannotti JP, Gerber C, eds. *Complex Revision Problems in Shoulder Surgery*. Philadelphia: Lippincott; 1997:99-116.
12. Gerber C, Nyffeller RW. Classification of glenohumeral joint instability. *Clin Orthop Relat Res*. 2002;400:65-76.
13. Gerber C, Werner CM, Macy JC, Jacob HA, Nyffeller RW. Effect of selective capsulorrhaphy on the passive range of motion of the glenohumeral joint. *J Bone Joint Surg Am*. 2003;85:48-55.
14. Gill TJ, Micheli LJ, Gebhard F, Binder C. Bankart repair for anterior instability of the shoulder: long-term outcome. *J Bone Joint Surg Am*. 1997;79:850-857.
15. Gill TJ, Zarins B. Open repairs for the treatment of anterior instability. *Am J Sports Med*. 2003;31:142-153.
16. Hall RH, Isaac F, Booth CH. Dislocations of the shoulder with special reference to accompanying small fractures. *J Bone Joint Surg Am*. 1959;41:489-494.
17. Helfet AJ. Coracoid transplantation for recurring dislocation of the shoulder. *J Bone Joint Surg Br*. 1958;40:198-202.
18. Hill HA, Sachs MD. The grooved defect of the humeral head: a frequently unrecognized complication of dislocation of the shoulder joint. *Radiology*. 1940;35:690-700.
19. Itoi E, Lee S-B, Amrami NN, Wender DE, An KN. Quantitative assessment of classic anteroinferior bony Bankart lesions by radiography and computed tomography. *Am J Sports Med*. 2003;31:112-118.
20. Itoi E, Lee S-B, Berglund LJ, Berge LL, An KN. The effect of a glenoid defect on anteroinferior stability of the shoulder after Bankart repair. *J Bone Joint Surg Am*. 2000;82:35-46.
21. Latarjet M. Technique de la butee coracoidienne preplenoidienne dans le traitement des luxations recidivantes de l'epaule. *Lyon Chir*. 1958;54:604-607.
22. Levine WN, Arroyo JS, Pollock RG, Flatow EL, Bigliani LU. Open revision stabilization surgery for recurrent anterior glenohumeral instability. *Am J Sports Med*. 2000;28:156-160.
23. Lo IKY, Parten PM, Burkhart SS. The inverted pear glenoid: an indicator of significant bone loss. *Arthroscopy*. 2004;20:169-174.
24. Millett PJ, Clavert P, Warner JJP. Current concepts review: open operative treatment for anterior shoulder instability: when and why? *J Bone Joint Surg Am*. 2005;87:419-432.
25. Miniaci A, Gish M. Management of anterior glenohumeral instability associated with large Hill-Sachs defects. *Tech Shoulder Elbow Surg*. 2004;5:170-175.
26. Mologne TS, Provencher MT, Menzel KA, Vachon TA, Dewing CB. Arthroscopic stabilization in patients with an inverted pear glenoid: results in patients with bone loss of the anterior glenoid. *Am J Sports Med*. 2007;35:1276-1283.
27. Montgomery WH Jr, Wahl M, Hettrich C, Itoi E, Lippitt SB, Matsen FA III. Anteroinferior bone-grafting can restore stability in osseous glenoid defects. *J Bone Joint Surg Am*. 2005;87:1972-1977.
28. Pagnani MJ. Open repair of anterior shoulder instability. In: Cole BJ, Sekiya JK, eds. *Surgical Techniques of the Shoulder, Elbow and Knee in Sports Medicine*. New York: Elsevier; 2008:103-113.
29. Pagnani MJ, Dome DC. Surgical treatment of traumatic anterior shoulder instability in American football players: two-to-six year follow-up in fifty-eight athletes. *J Bone Joint Surg Am*. 2002;84:711-715.
30. Plausinis D, Bravman JT, Heywood C, Kummer FJ, Kwon YW, Jazrawi LM. Arthroscopic rotator interval closure: effect of sutures on glenohumeral motion and anterior-posterior translation. *Am J Sports Med*. 2006;34:1656-1661.
31. Provencher MT, Mologne TS, Hongo M, Zhao K, Tasto JP, An KN. Arthroscopic versus open rotator interval closure: biomechanical evaluation of stability and motion. *Arthroscopy*. 2007;23:583-592.
32. Richards RR, An K-N, Bigliani LU, et al. A standardized method for the assessment of shoulder function. *J Shoulder Elbow Surg*. 1994;3:347-352.
33. Rowe CR, Patel D, Southmayd WW. The Bankart procedure: a long-term end-result study. *J Bone Joint Surg Am*. 1978;60:1-16.
34. Rowe CR, Zarins B, Ciuillo JV. Recurrent anterior dislocation of the shoulder after surgical repair: apparent causes of failure and treatment. *J Bone Joint Surg Am*. 1984;66:159-168.
35. Schauder KS, Tullos HS. Role of the coracoid bone block in the modified Bristow procedure. *Am J Sports Med*. 1992;20:31-34.
36. Scheibel M, Magosch P, Lichtenberg S, Habermeyer P. Open reconstruction of anterior glenoid rim fracture. *Knee Surg Sports Traumatol Arthrosc*. 2004;12:568-573.
37. Sekiya JK, Wickwire AC, Stehle JH, Debski RE. A biomechanical analysis of humeral head lesions in the glenohumeral joint. In: *73rd Annual Meeting Proceedings*. Rosemont, IL: American Academy of Orthopaedic Surgeons; 2006:680-681.
38. Sugaya H, Moriishi J, Dohi M, Kon Y, Tsuchita A. Glenoid rim morphology in recurrent anterior glenohumeral instability. *J Bone Joint Surg Am*. 2003;85:878-884.
39. Sugaya H, Moriishi J, Kanisawa I, Tsuchiya A. Arthroscopic osseous Bankart repair for chronic recurrent traumatic anterior glenohumeral instability. *J Bone Joint Surg Am*. 2005;87:1752-1760.
40. Trillat A. Traitement de la luxation recidivante de l'epaule: considerations, techniques. *Lyon Chir*. 1954;49:986-993.
41. Warner JJP, Gill TJ, O'Hollerhan JD, Pathare N, Millett PJ. Anatomical glenoid reconstruction for recurrent anterior glenohumeral instability with glenoid deficiency using an autogenous tricortical bone graft. *Am J Sports Med*. 2006;34:205-212.
42. Weber BG, Simpson LA, Hardegger F. Rotational humeral osteotomy for recurrent anterior dislocation of the shoulder associated with a large Hill-Sachs lesion. *J Bone Joint Surg Am*. 1984;66:1443-1450.
43. Young DC, Rockwood CA Jr. Complications of a failed Bristow procedure and their management. *J Bone Joint Surg Am*. 1991;73:969-981.
44. Zabinski SJ, Callaway GH, Cohen S, Warren RF. Revision shoulder stabilization: 2- to 10-year results. *J Shoulder Elbow Surg*. 1999;8:58-65.
45. Zuckerman JD, Matsen FA III. Complications about the glenohumeral joint related to the use of screws and staples. *J Bone Joint Surg Am*. 1984;66:175-180.